

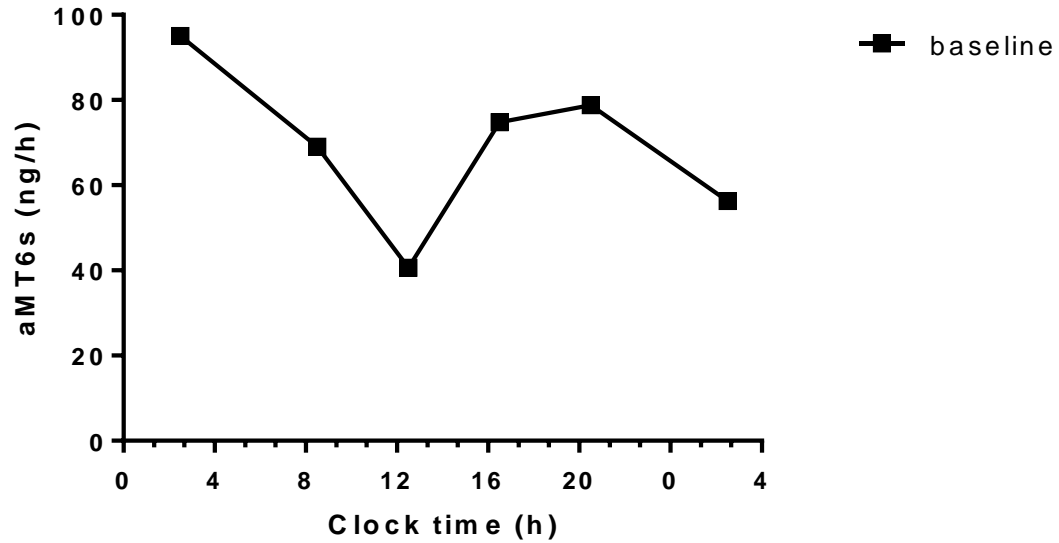Figure 1A. 67-year old female with alcohol-related cirrhosis, admitted for hepatic encephalopathy, Child-Pugh C12, MELD 17, standard lighting room

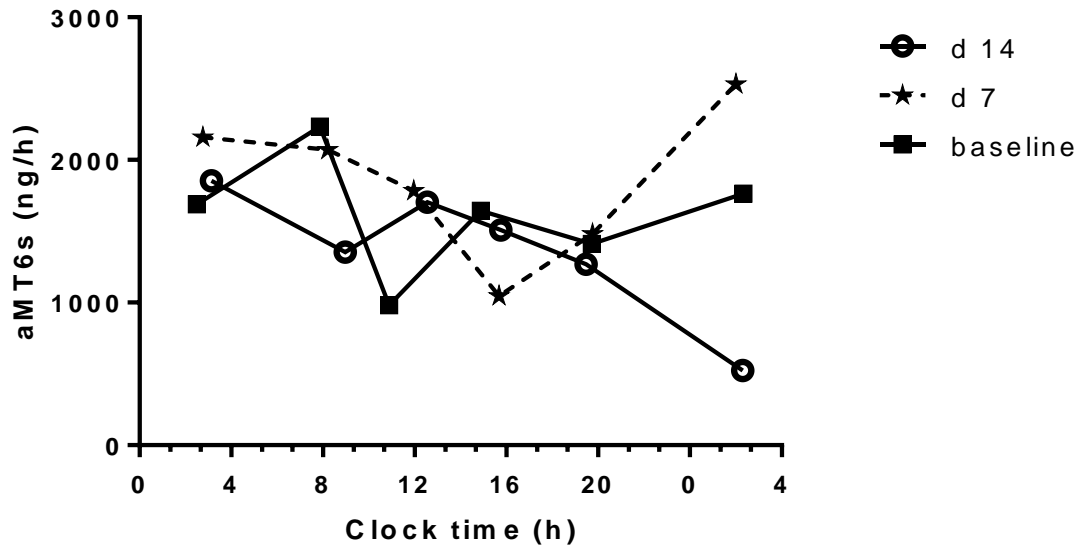


Figure 1B. 52-year old male with HCV-related cirrhosis, admitted for tense ascites, Child-Pugh C12, MELD 27, standard lighting room

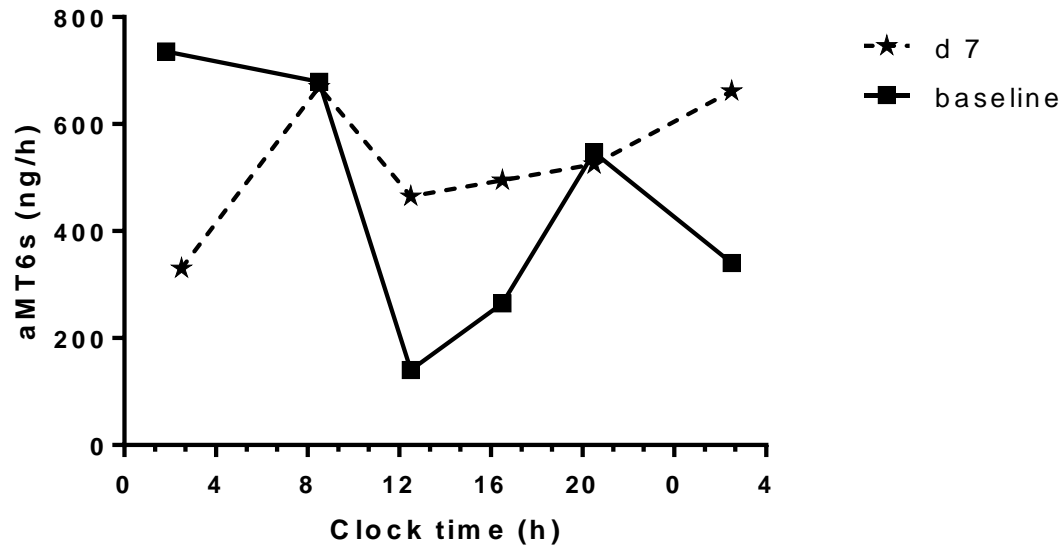


Figure 1C. 60-year old male with HCV-related cirrhosis, admitted for tense ascites, Child-Pugh C10, MELD 13, standard lighting room

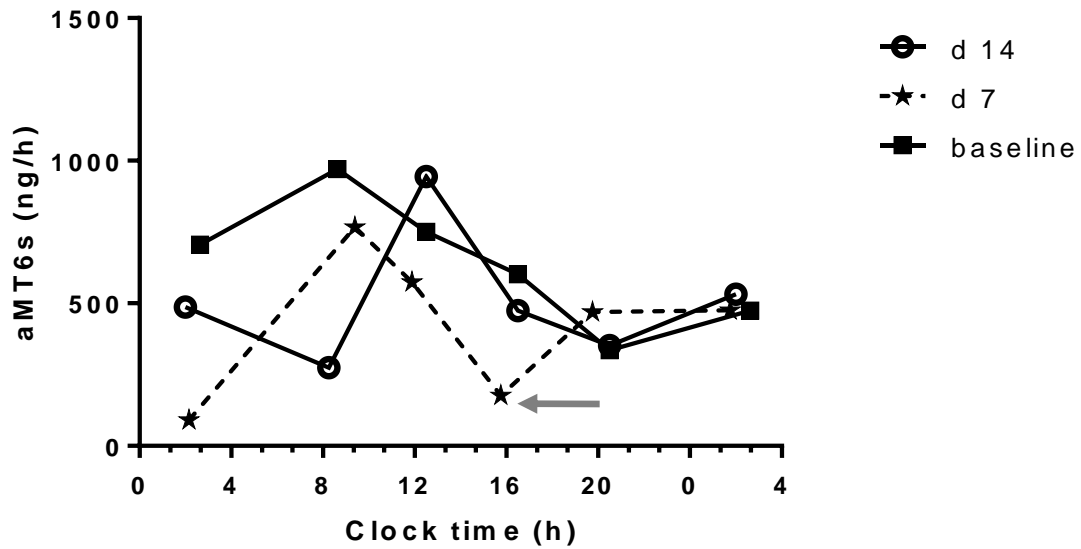


Figure 1D. 55-year old male with HCV-related cirrhosis, admitted for hepato-renal syndrome, Child-Pugh C13, MELD 32, intervention room

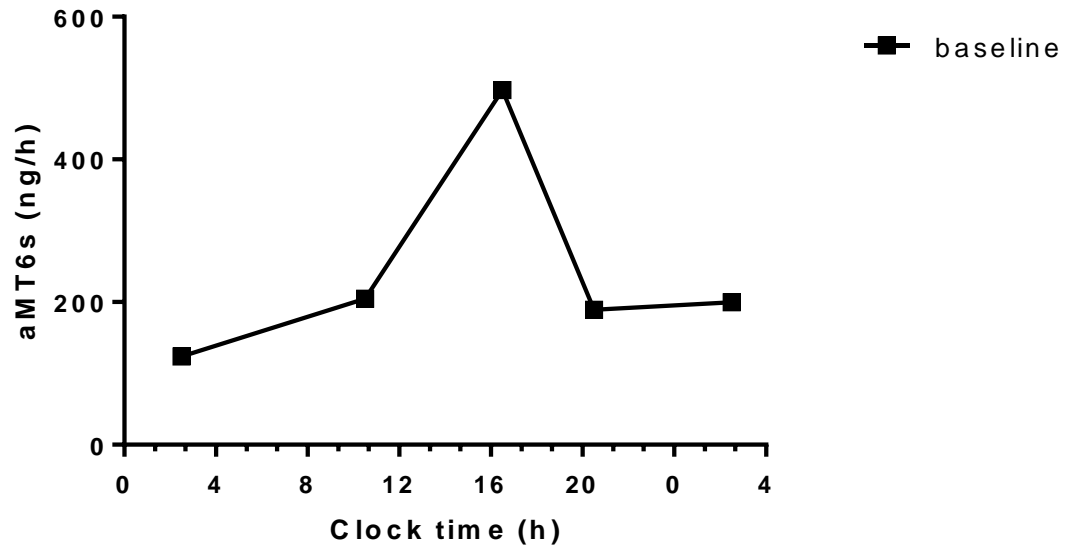


Figure 1E. 61-year old male with alcohol-related cirrhosis, admitted for hepato-renal syndrome, Child-Pugh B9, MELD 30, standard lighting room

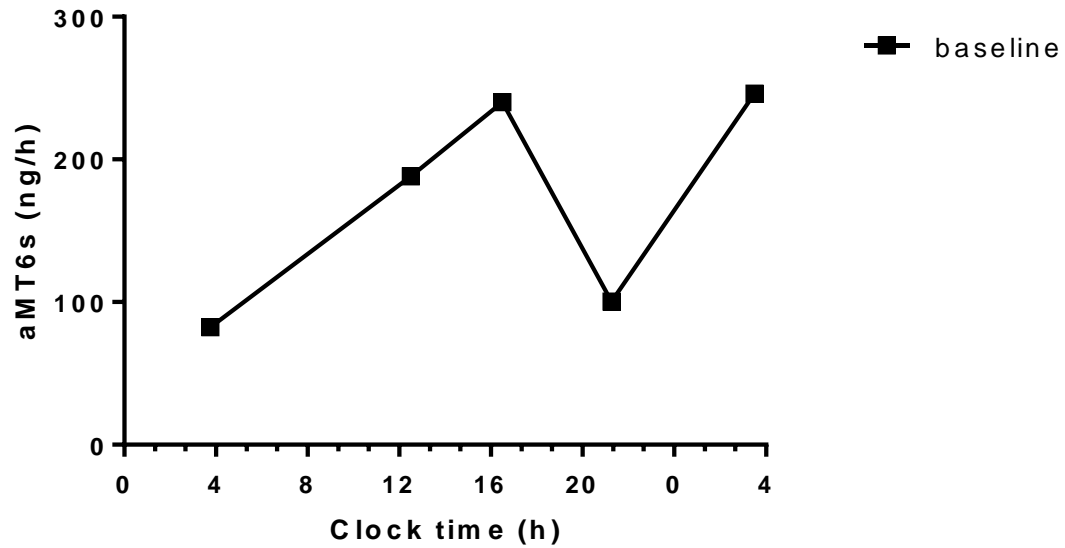


Figure 1F. 27-year old male with HBV-related cirrhosis, admitted for hepatic encephalopathy, Child-Pugh C13, MELD 26, intervention room

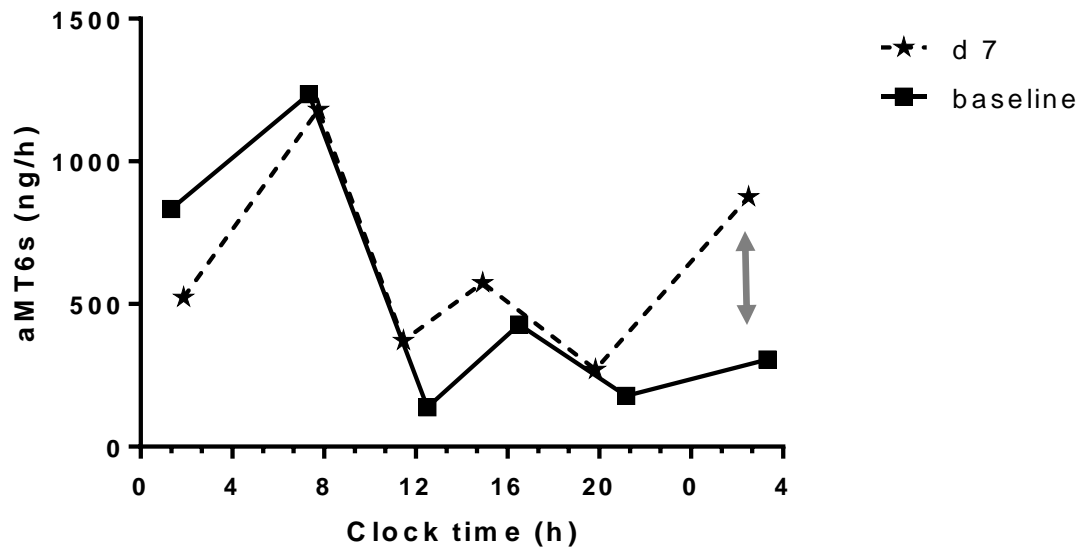


Figure 1G. 48-year old male with HCV and alcohol-related cirrhosis, admitted for tense ascites, Child-Pugh C10, MELD 17, intervention room