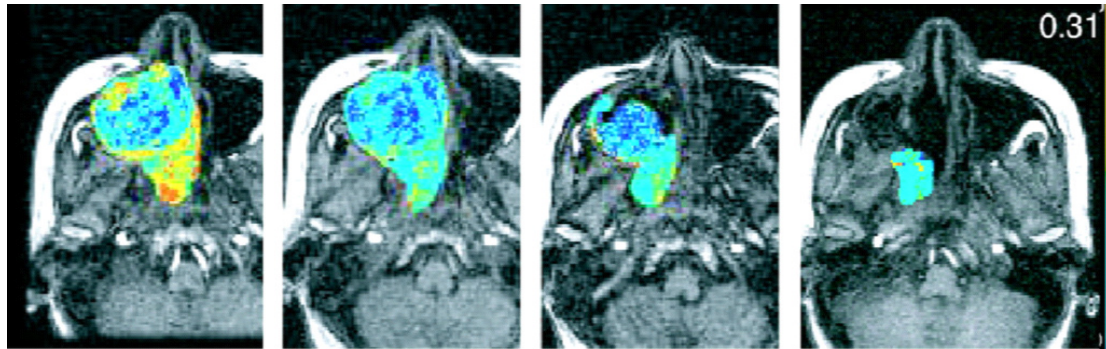


Figure 2

DCE-MRI image from a patient with brain tumour undergoing treatment with an experimental anti-VEGF agent AG-013736 at baseline, day 2, week 4 and week 8



(Please note that permission to use this picture has been requested from Pfizer)